

Cartilage Sutures for a Large Nasal Defect

Daniel Condie, MD; Ramin Fathi, MD; Rajiv I. Nijhawan, MD

The authors highlight the use of cartilage sutures in nasal reconstruction. Interdomal cartilage sutures may decrease defect size and contribute to a good cosmetic result.

Cutis. 2020;105:44-45.

Practice Gap

A 69-year-old man underwent staged excision for an invasive melanoma (0.4-mm Breslow depth; stage Ia) of the right dorsal nose. Two stages were required to achieve clear margins, leaving a 3.0×2.5-cm defect involving the nasal dorsum, right nasal sidewall, and nasal supratip (Figure 1). He declined any multistage repair and preferred a full-thickness skin graft (FTSG) over any interpolation flap.

Given the size of our patient's defect, primary repair was not possible and second intention healing may have resulted in a suboptimal cosmetic outcome, potential alar distortion, and prolonged healing. No single local flap, such as the dorsal nasal rotation flap, crescentic advancement flap, bilobed flap, and Rintala flap, would have provided adequate coverage. A FTSG of the entire defect would not have been an ideal tissue match, and given the limited surrounding laxity, a Burow FTSG would have required the linear repair to extend well into the forehead with a questionable cosmetic outcome.

The Technique

We opted to repair the defect using a combination of local flaps for a single-stage repair. Using the right cheek reservoir, a crescentic advancement flap was performed to restore the right nasal sidewall as best as possible with a standing cone taken superiorly. To execute this flap, an incision was made extending from the alar sulcus into the nasolabial fold while preserving the apical triangle of the upper cutaneous lip. The flap was elevated submuscularly on the nose, and broad undermining was performed in

the subcutaneous plane of the medial cheek. A crescentic redundancy above the alar sulcus was excised, and periosteal tacking sutures were placed to both help advance the flap and to recreate the nasofacial sulcus.¹

Next, a nasal tip spiral/rotation flap was designed to restore the remaining nasal defect.² An incision was made at the right inferiormost aspect of the defect and extended along the inferior border of the nasal tip as it crossed the midline to the left side of the nose. After incising and elevating the flap in the submuscular plane, there was not enough of a tissue reservoir to cover the entire remaining nasal defect.

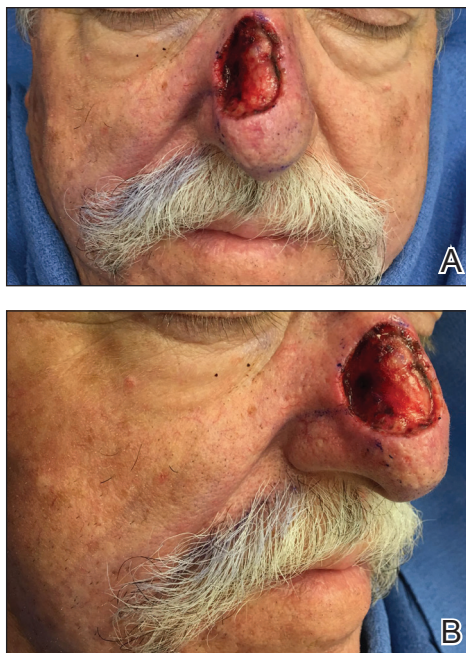

FIGURE 1. A and B, Surgical defect.

Dr. Condie is from The Center for Dermatology and Plastic Surgery, Gilbert, Arizona. Dr. Fathi is from Southwest Skin Specialists, Scottsdale, Arizona. Dr. Nijhawan is from the Department of Dermatology, University of Texas Southwestern Medical Center, Dallas.

The authors report no conflict of interest.

Correspondence: Daniel Condie, MD, The Center for Dermatology and Plastic Surgery, 3530 S Val Vista Dr, Ste B-109, Gilbert, AZ 85297 (dlcondie@gmail.com).

To resolve this intraoperative conundrum, simple interrupted sutures were placed into the nasal cartilage at midline to narrow the structure of the nose (Figure 2). Three 4-0 polyglactin 910 sutures were placed beginning with the upper lateral cartilages and extending inferiorly to the lower lateral cartilages. Narrowing the nasal cartilages allowed for a smaller residual defect. The nasal tip rotation flap was then spiraled into place with adequate coverage. Some of the flap tip was trimmed after the superior aspect of the rotation flap was sutured to the inferior edge of the crescentic advancement flap. The immediate postoperative appearance is shown in Figure 3.

At 4-month follow-up, intralesional triamcinolone was injected into the slight induration at the right nasal tip. At 7-month follow-up, the patient was pleased with the cosmetic and functional result (Figure 4).

Practice Implications

Cartilage sutures highlight an underutilized technique in nasal reconstruction, with few cases reported in the dermatologic surgery literature.^{3,4} The interdomal suture is placed through the left and right lower lateral cartilages to help narrow and redefine the nasal tip.⁵ Reported techniques include simple interrupted suture or horizontal mattress suture. Suture material for nasal cartilage may be permanent (nylon or polypropylene) or long-lasting

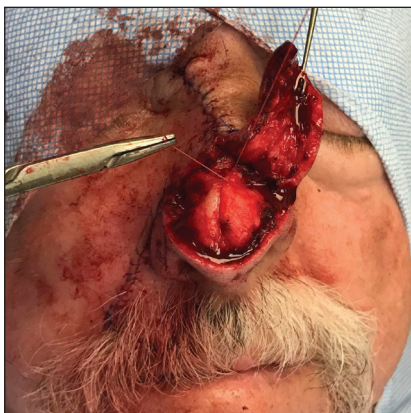

FIGURE 2. Simple interrupted sutures placed into the nasal cartilage to narrow the nose.

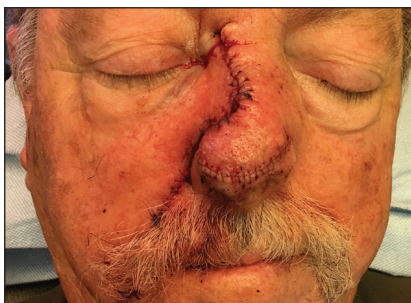

FIGURE 3. Immediate postoperative appearance.

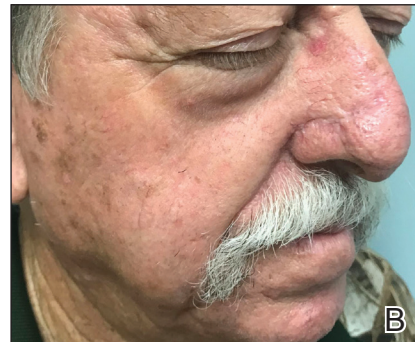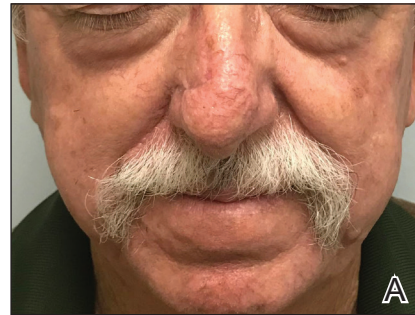


FIGURE 4. A and B, Postoperative follow-up at 7 months.

(polydioxanone or polyglactin 910).⁵ The use of interdomal sutures has been reported to narrow and decrease the volume of nasal tip defects prior to repair with local flaps and FTSG.^{3,4} In addition to the interdomal suture of the lower lateral nasal cartilage, simple interrupted sutures were placed in the upper lateral cartilages that created an even smaller residual defect. Sutures of the nasal cartilage may be a good option for select patients in dermatologic reconstruction, allowing for a simple repair with the added benefit of improved cosmetic result.

A combination of local flaps may be used to repair large nasal defects involving multiple subunits, especially in patients who decline multistage reconstruction. A nasal tip rotation/spiral flap can be considered for the appropriate nasal tip defect. Suturing the nasal cartilage with either permanent or long-lasting suture can narrow the cartilage and facilitate flap coverage for nasal defects while also improving the appearance of patients with wide prominent lower noses.

REFERENCES

1. Smith JM, Orseth ML, Nijhawan RI. Reconstruction of large nasal dorsum defects. *Dermatol Surg.* 2018;44:1607-1610.
2. Snow SN. Rotation flaps to reconstruct nasal tip defects following Mohs surgery. *Dermatol Surg.* 1997;23:916-919.
3. Malone CH, Hays JP, Tausend WE, et al. Interdomal sutures for nasal tip refinement and reduced wound size. *J Am Acad Dermatol.* 2017;77:E107-E108.
4. Pelster MW, Behshad R, Maher IA. Large nasal tip defects-utilization of interdomal sutures before Burow's graft for optimization of nasal contour. *Dermatol Surg.* 2019;45:743-746.
5. Gruber RP, Chang E, Buchanan E. Suture techniques in rhinoplasty. *Clin Plast Surg.* 2010;37:231-243.